

## Effective treatment with proven results by homeopathy

The best treatment for any disease has been proven by Constitutional Homeopathy at Homeocare International. Lakhs of patients have experienced effective results, through us.



### Our Advanced Speciality Treatments in:

- Diabetes
- PCOD
- Arthritis
- Disc Problems
- Infertility
- Sexual Problems
- Spondylosis
- Asthma-Allergy
- Thyroid
- Hormone Problems
- Joint Pains
- Psoriasis

Scan for Superstar Krishna video on Homeocare International



**HOMEOCARE<sup>®</sup>**  
**INTERNATIONAL**  
WORLD-CLASS HOMEOPATHY

An ISO 9001:2008 Certified clinic with German Accreditation

[www.homeocare.in](http://www.homeocare.in)



**FREE CONSULTATION 955 000 1188 / 99** TOLL-FREE 1800 102 2202

**TELANGANA:** Hyderabad (Abids, Begumpet, Dilukhnagar, Jubilee Hills, Kukatpally, Masab Tank, Miyapur), Hanumakonda.


**ANDHRA PRADESH:** Vijayawada, Visakhapatnam, Tirupati, Rajahmundry, Guntur.

**KARNATAKA:** Bengaluru (Jayanagar, Malleshwaram, Indira Nagar), Hubballi, Mangaluru, Davangere, Ballari, Mysuru, Kalaburgi.

**TAMIL NADU:** Chennai (Aminjikarai, C.I.T. Nagar, Tambaram), Coimbatore, Madurai, Trichy.

**HOMEOCARE**  
**INTERNATIONAL**  
**Arogya**

Be Healthy, Be Happy  
Volume-2



WISHING EVERYONE  
A VERY HAPPY & HEALTHY

**UGADI**



**HOMEOCARE<sup>®</sup>**  
**INTERNATIONAL**  
WORLD-CLASS HOMEOPATHY



### Editor's Note

"Hello, I welcome you to another edition of our magazine with much happiness and sincerity."

### Festive Issue

In this season of festivals, we bring you happy stories of people who have been cured of their ailments at Homeocare International. I would like to thank our entire staff for their relentless hard work and dedication and a special mention to the doctors who took time in extending support and contributed to this magazine. The forthcoming issues will have more such cases of cured patients and please do let us know about any spectacular cases. As we continue to progress I would like to wish you all, a prosperous and successful year and best wishes for the festive season.

Dr. Rohit Morlawar  
Editor-in-Chief

## Celebrating Good Health Cover Note

In this season of festivities, Homeocare International would like to thank each and every one in our team, who have helped us in spreading the festive cheer amongst patients and their families. Everyone deserves to be happy and Homeocare International dedicates itself to deliver such happiness by curing numerous chronic cases. Homeocare International is sure to progress further in spreading much more happiness across the nation. This festive season Homeocare International wishes you all good health and prosperity.

**Co-Editors:** Medical Audit Team  
**Chief Advisor:** Dr. Sudheer Reddy

**Contributors:**  
Dr. Ramadas      Dr. Madhavi      Dr. Venkatnarayana  
Dr. Anil            Dr. Surender Reddy      Dr. Karthikeyan  
Dr. Sneha B.      Dr. Mullai

**Design:**  
White Thoughts & Branding

## Renal Calculi

### BEFORE

treatment at  
Homeocare International

### AFTER

treatment at  
Homeocare International

**BEFORE**

**BHARAT SCANS**  
Innovation at work

Patient Name	Mr. S.CHANDRU	Age/Sex	29 Years / Male
Patient ID	12147737	Visit No	1
Referred by	Dr. PANDIYA MEENA E MBBS	Visit Date	02/04/2014

**MR. CHANDRU (CITATSH)**

**ULTRASOUND OF ABDOMEN AND PELVIS**

**MR. CHANDRAN (CITATSH)**      AGE 29  
CR. NO 4170      SEX MALE  
REF. CONSULTANT SELF      DATE 13.07.2014

**ULTRASOUND OF ABDOMEN AND PELVIS**

Thanks for the referral of this patient for Ultrasound study.

**LIVER:** Normal in size and shows homogenous echotexture. No focal pathology. No evidence of dilatation of IHBR. Portal vein appears normal.

**GALL BLADDER:** Adequately distended and shows normal wall thickness. CBD appears normal. No calculus / polyp / sludge.

**PANCREAS:** Normal in size and shows homogeneous echo pattern: No focal or diffuse pathology; pancreatic duct in not dilated.

**SPLEEN** appears normal in size and shows homogenous echotexture.

**RIGHT KIDNEY:** Size measuring 9.3 x 4.3 cm. Cortical echoes are normal. CMD normal. No focal lesion. No evidence of calculus. Collecting system is normal.

**LEFT KIDNEY:** Size measuring 10.9 x 4.8 cm. Cortical echoes are normal. CMD normal. No focal lesion. No evidence of calculus. Collecting system is normal.

**AORTA & IVC:** Normal in caliber. No demonstrable para aortic nodes.

**URINARY BLADDER** appears normal. There is no definite evidence of wall thickening or intra luminal pathology.

**PROSTATE** appears normal in size and measuring 3.1 x 2.2 x 2.8 cm. Volume 10.58 ml.

**PERITONEUM:** No evidence of free fluid.

**IMPRESSION:**

➤ Normal sonographic study of the solid abdominal organs.

DR. K. SHIVASHANKAR DMRD, DNB,  
Consultant Radiologist

Quality is our Image

www.bharatiscans.com

**AFTER**

**MNRI Scans Pvt. Ltd.**

1A, 1st Main Road, C.I.T. Nagar, Nandanam, (Opp. South Usman Road, T.Nagar), Chennai - 35. Ph: 2434 4892 / 2434 4893 / 2433 2549 / 9562 9207

**MR. CHANDRAN (CITATSH)**      AGE 29  
CR. NO 4170      SEX MALE  
REF. CONSULTANT SELF      DATE 13.07.2014

**ULTRASOUND OF ABDOMEN AND PELVIS**

Thanks for the referral of this patient for Ultrasound study.

**LIVER:** Normal in size and shows homogenous echotexture. No focal pathology. No evidence of dilatation of IHBR. Portal vein appears normal.

**GALL BLADDER:** Adequately distended and shows normal wall thickness. CBD appears normal. No calculus / polyp / sludge.

**PANCREAS:** Normal in size and shows homogeneous echo pattern: No focal or diffuse pathology; pancreatic duct in not dilated.

**SPLEEN** appears normal in size and shows homogenous echotexture.

**RIGHT KIDNEY:** Size measuring 9.3 x 4.3 cm. Cortical echoes are normal. CMD normal. No focal lesion. No evidence of calculus. Collecting system is normal.

**LEFT KIDNEY:** Size measuring 10.9 x 4.8 cm. Cortical echoes are normal. CMD normal. No focal lesion. No evidence of calculus. Collecting system is normal.

**AORTA & IVC:** Normal in caliber. No demonstrable para aortic nodes.

**URINARY BLADDER** appears normal. There is no definite evidence of wall thickening or intra luminal pathology.

**PROSTATE** appears normal in size and measuring 3.1 x 2.2 x 2.8 cm. Volume 10.58 ml.

**PERITONEUM:** No evidence of free fluid.

**IMPRESSION:**

➤ Normal sonographic study of the solid abdominal organs.

DR. K. SHIVASHANKAR DMRD, DNB,  
Consultant Radiologist

**Myth 3:** Disease diagnosis is not important in Homeopathy

**Fact:** Diagnosis means naming of the disease, it helps in understanding prognosis of the disease. So, diagnosis is important even for a Homeopathy doctor. Homeopathy treatment not only depends on disease diagnosis, many other things also play a major role in treating diseases. In Homeopathy we treat the disease and the person as a whole.

**Myth 4:** Homeopathic medicines are unsafe for pregnant women

**Fact:** Homeopathy is the safest and ideal medicine for pregnant women for problems like, morning sickness, nausea, anaemia, backache, cramps, heartburn, diarrhoea, skin allergies, blood pressure, emotional distress, etc. which usually occur during pregnancy. And it is also safe for the growing baby.

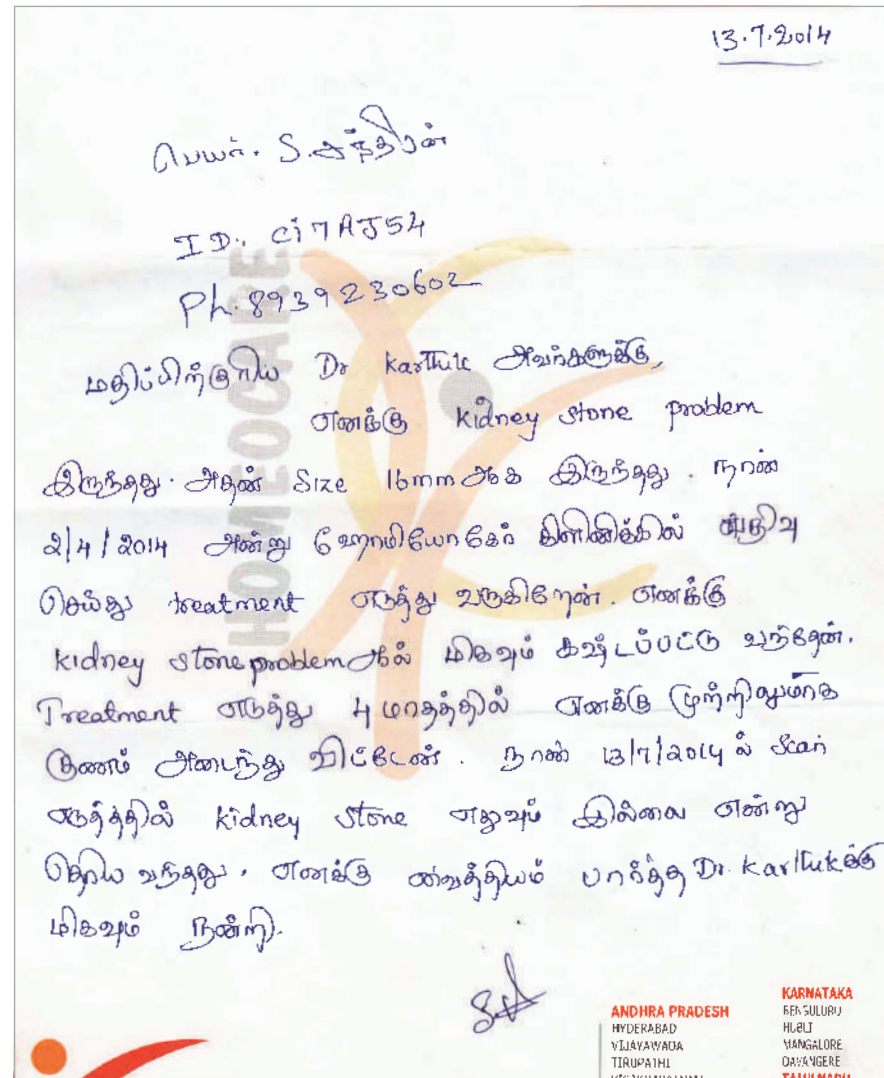
**Myth 5:** Homeopathy is only a herbal treatment

**Fact:** Homeopathy medicines are not herbal, because they are never used in crude form, they are not only prepared from plants, we extract the crude substances from various sources like animals, minerals etc and their preparation undergo a process of potentiation. So that it works in dynamic level to cure diseases completely.

# Renal Calculi cured, surgery avoided

Case Study of Dr. Karthikeyan

A solution for Renal Calculi without surgery by using Homeopathic medicines at Homeocare International. The reports before treatment shows 9.3mm calculus in proximal ureter and after 3 months of treatment, report shows how Homeopathy prevented surgery.



## Homeopathy myths and facts

**Myth 1:** There are many diet restrictions on homeopathic treatment

**Fact:** It's a false opinion regarding diet during homeopathic medications food items like onion, garlic and mint etc. are restricted. Homeopathic medicines when given can be inactivated by certain substances, but not in all medicines. To avoid this small problem ideally patients are advised to abstain food and beverages 15 min before and after taking homeopathic medicines.

**Myth 2:** Homeopathy is not for first aid

**Fact:** Homeopathy works wonders in first aid, in cases of sprains and strains, concussions, minor cuts and wounds, scalds, burns, sunburn, bites & stings, blisters, toothache, bleeding haemorrhoids, hiccups, etc.



## Chairman's Message

Greetings for the festive season

We at Homeocare International are a family of 300+ experienced and dedicated doctors, who relentlessly work towards a common goal to make India a land of healthy and happy people.

On this occasion I would like to thank all the staff and Doctors for putting their effort in making Homeocare International, the most preferred homeopathy clinic to cure and treat innumerable chronic diseases.

We at Homeocare International are committed to provide the highest quality of healthcare to patients, we have seamlessly integrated the traditional methods of homeopathy into world-class and state-of-the-art infrastructure, cutting-edge technology and comprehensive information systems. We have also been able to set the highest level of benchmarks for effective treatment of chronic diseases. This festive season I would like to thank you for your effort and zeal to make homeopathy a trusted medicine. Let's celebrate our success and I wish you much more happiness and prosperity in the future.

With regards,  
 Dr. Srikant Morlawar,  
 Chairman & Managing Director,  
 Homeocare International Pvt. Ltd.

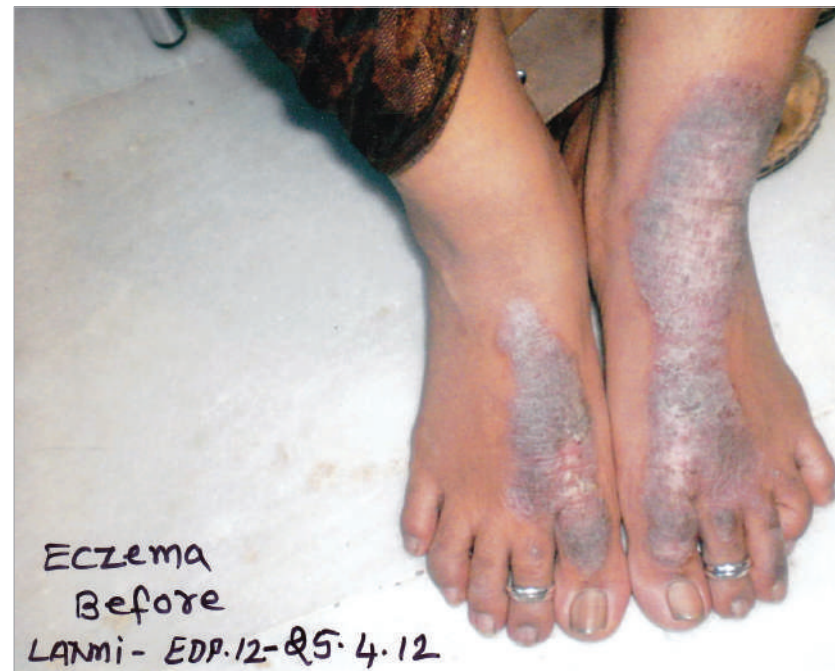# A case of chronic Eczema

Case Study of Mrs. Laxmi Reddy

A case of chronic Eczema treated with Homeopathy. This patient took various treatments for the past 10 years but without any satisfactory result. After taking treatment at Homeocare International, her skin was free from Eczema. This is a sign of true improvement.

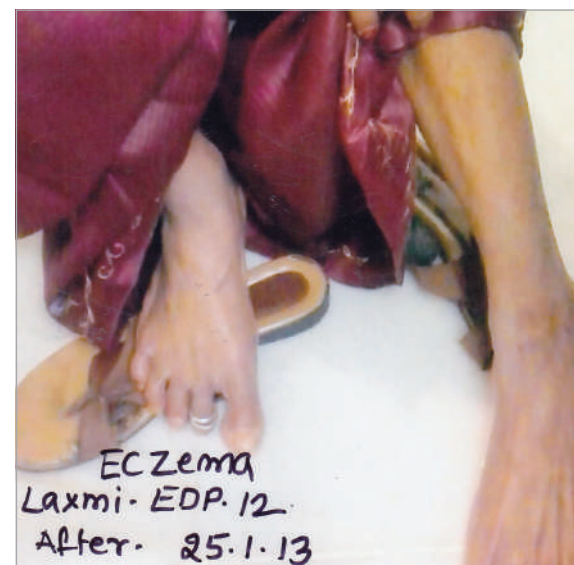
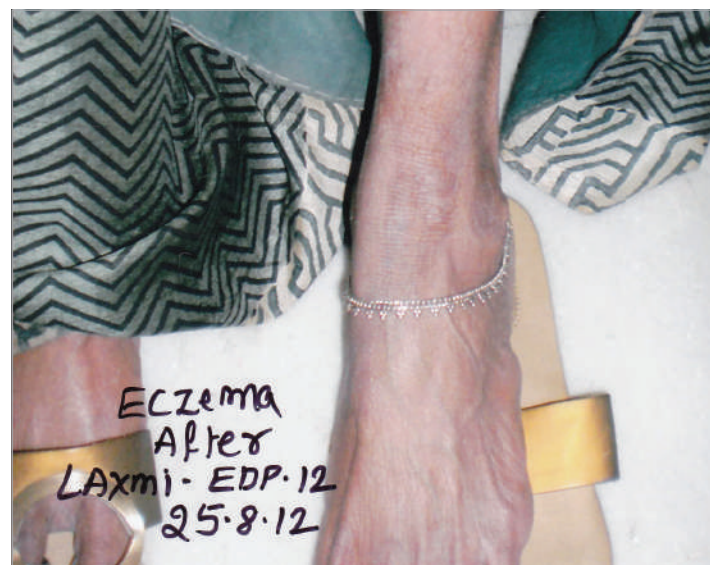## BEFORE

treatment at Homeocare International



## AFTER

treatment at Homeocare International



# Thyroid

**AFTER** treatment at Homeocare International

## Scan Point Diagnostics

*for a better life*

**FACILITIES AVAILABLE**

- High Resolution
- Ultrasound Scan
- Colour Doppler
- Clinical Lab
- Endoscopy
- Physiotherapy
- X-Ray
- ECG
- Echo
- TMT

NAME : MRS. BAVITHA	AGE : 26 YEARS	SEX : FEMALE
REF BY : C/O BALAJI DIAGNOSTICS	SCAN NO: 2293/13	DATE: 16/02/2013

**USG – Thyroid scan**

**FINDINGS :**

Both lobes of the thyroid are normal in size, shape, position & echo texture

Isthmus appear normal

Right lobe of thyroid measures 2.9 x 1.6 x 3.5cms

Left lobe of thyroid measures 2.3x 1.3 x 2.6 cms

Isthmus measures – 2.8mm

Neck vessels grossly appears normal.

No enlarged lymphnode seen

**IMPRESION: Normal thyroid scan.**

*(Signature)*  
**DR. RAMALINGAIAH, MBBS, MDRD,**  
Consultant Radiologist & Ultrasonologist

No. 40, First Floor, BDA Complex, Nagarabhavi, Bangalore - 560 072.  
Ph. : 23212827, 98455 14464, 99015 77335

# Thyroid treatment with Homeopathy

A Case Study

A case of 24-year old female presented with Thyroid enlargement. Before treating, Thyroid scan showed diffuse enlargement of both lobes of Thyroid. After 8 months of treatment, repeat scan showed absolutely normal report.

**BEFORE** treatment at Homeocare International

Phone : 23712175  
23717777  
(Ext. 230)

**JINDAL RURAL CHARITABLE HOSPITAL**  
JINDAL NAGAR, TUMKUR ROAD, BANGALORE-560 073.  
RADIOLOGY DEPARTMENT

---

ULTRASONOGRAPHY REPORT MLBF-56  
(Diagn. Pt.)

**NAME:** MISS. BANITHA **24Y/F** **15158**

**INVESTIGATION; ULTRASONOGRAPHY OF THYROID**

**REF BY DOCTOR: PADMAVATHI** **JRCH** **16.06.12.**

**THYROID SCAN**

B-Mode ultrasonography of the thyroid was performed using 7.5 MHz probe.

**BOTH LOBES:** Right lobe measures 33 X 17 X 22 mm .  
Left lobe measures 34 X 17 X 18 mm .


Diffused enlargement of both lobe of thyroid

No evidence of calcification

No hyper/hypoechoic lesion

Isthmus 4mm appears normal.

**IMPRESSION: DIFFUSED ENLARGMENT OF BOTH LOBES OF THYROID**

For   
**DR. SUJITH**  
**RADIOLOGIST**

# Eczema

Patient Testimonial

**HOMEOCARE**  
**arogyā**  
Be Healthy, Be Happy

**HOMEOCARE INTERNATIONAL**  
Pvt. Ltd.  
LEADERS IN WORLD-CLASS HOMEOPATHY  
An ISO : 2008 Certified clinics with German Accreditation

25-1-2013

My name is lakshmi.reddy bearing my ID NO. EDP-12/BAT-51. have consulted for the treatment of Eczema. Already I have consulted and took the treatment for Eczema for the past 10 years. in India and abroad. but nowhere I didn't get cured I have consulted "Homeocare International Jubilee hills branch" for my skin problem. on 25/4/12 and Dr. PV Suresh Reddy was advised me to take treatment for a period of 1 year. After 1<sup>st</sup> & 2<sup>nd</sup> consultations Eczema is cleared upto 20-30%. Next subsequent visits Eczema is completely cured 90-95%. Before and after photos are attached.

*P. Lakshmi Reddy*

**ANDHRA PRADESH**  
HYDERABAD  
VIJAYAWADA  
TIRUPATHI  
VISAKHAPATNAM  
RAJAHMUNDRY  
GUNTUR  
HANUMAKONDA

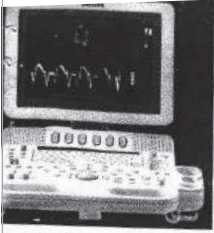
**KARNATAKA**  
BENGALURU  
HUBLI  
MANGALORE  
DAVANGERE  
**TAMILNADU**  
CHENNAI  
COIMBATORE  
MADHURAI

Registered Office : # 63, Sindhi Colony, S.P. Road, Secunderabad - 500 003,  
Andhra Pradesh, INDIA. Ph : 8885037219 / 9885747979 / 9849056637  
[www.homeocare.in](http://www.homeocare.in)

# Uterine Fibroid? No longer a worry at all

A Case Study

It is time to prove that Homeopathy can offer results in surgical disease like Uterine Fibroids. Here is a case with bulky uterus and subserosal fibroid measuring 2.8x2.6cm. After 8 months of treatment in Homeocare International, the patient was again sent for ultrasonic revision that confirmed no evidence of fibroid.



## RAGASUMA

### SCAN & DIAGNOSTIC CENTRE

**Dr. B. VIJAYASREE**  
M.B.B.S., DMRD  
Cell : 9705698486

Regd. No. 34775

C/o. Suguna Children's Hospital  
# 6-8-90, Behind Ganesh Temple  
M.G. Road, KOTHAGUDEM - 507 101

---

Patient name: Amuthavali Date: 6-9-2010

Age/Sex: 36Y/ F

Ref by: Dr. Vandana Venkateswarlu MD

**Liver:** Normal in size and contour. Parenchymal echotexture is normal. Hepatic and portal venous systems are normal. C.B.D and Portal vein are normal in caliber. No I.H.B.D. No e/o of any mass lesion.

**G.B.:** Physiologically distended well. No e/o any calculi/mass lesion. Wall thickness normal.

**SPLEEN:** Normal in size and echotexture. No focal lesion seen. Splenic vein normal.

**PANCREAS:** Normal in size and echotexture. No e/o any calcifications/mass lesion. Pancreatic duct normal. No e/o any peripancreatic collections.

**RT KIDNEY:** Normal in size and echotexture. No e/o Calculi/mass lesion. Collecting system is normal. Corticomedullary differentiation is well made out. Perirenal space is normal.

**LT KIDNEY:** Normal in size and echotexture. No e/o Calculi/mass lesion. Collecting system is normal. Corticomedullary differentiation is well made out. Perirenal space is normal.

**I.V.C and AORTA:** Normal in caliber. No paraaortic lymphadenopathy.

**U.B.:** Distended well with normal contour. No E/O calculi/mass lesion. Wall thickness normal.

**UTERUS:** Bulky (10.1x4.6x5.1cm). Anteverted. Endometrial echo is in midline and normal. Hypoechoic mass lesion measuring 2.8x2.6cm noted posteriorly, subserosally in the fundus of the uterus.


**OVARIES:** Both ovaries normal in size, shape and echogenicity. No adnexal masses.

**OTHERS:** No evidence of free fluid in pleural or peritoneal cavity.

Bowels are normal with normal peristaltic activity.

**Impression:** Subserosal fibroid in the fundus of Uterus posteriorly.

Bulky Uterus.

  
**Dr. B. VijayaSree**  
Radiologist

Please correlate clinically.

**BEFORE**

treatment at  
Homeocare  
International

# Ovarian Cyst


Patient Testimonial

**HOMEOCARE**  
*arogyā*  
Be Healthy, Be Happy

Date: 08/08/14

Patient Name: Amuthavali

ID NO : CITBR21




**HOMEOCARE**  
**INTERNATIONAL**  
LEADERS IN WORLD-CLASS HOMEOPATHY  
An ISO : 2008 Certified clinics with German Accreditation

I am K. Amuthavali, Age 42 years.

I have taking treatment in homeocare for past 8 months for back pain, PLOD and skin allergy. My problems are completely better. My PLOD problem is fully cured. Thanks to Dr. Mullai and homeocare International.

*K. Amuthavali*



Registered Office # 63, Sindhi Colony, S.P. Road, Secunderabad - 500 003, Andhra Pradesh, INDIA. Ph : 8885037219 / 9885747979 / 9849056637  
[www.homeocare.in](http://www.homeocare.in)

**ANDHRA PRADESH**  
HYDERABAD  
VIJAYAWADA  
TIRUPATHI  
VISAKHAPATNAM  
RAJAHMUNDRY  
GUNTUR  
HANUMAKONDA

**KARNATAKA**  
BENGALURU  
HUBLI  
MANGALORE  
DAVANGERE  
**TAMILNADU**  
CHENNAI  
COIMBATORE  
MADHURAI

4

21

Arogya Book-Ugadi\_NEW\_Final.indd Spread 6 of 14 - Pages(4, 21)

07/03/15 7:27 PM

# Think Homeopathy for Ovarian Cyst

Case Study of Mrs. Amrutha Valli

Homeopathy can offer solutions to Ovarian Cyst also. This is a case of a female patient presented with left ovarian large cyst measuring 5.3 - 5.1 cm. in size. After 8 months of treatment USG study showed of uterus and ovaries appeared within normal limits with no evidence of cyst seen at ovaries.

## BEFORE

treatment at Homeocare International

**BEFORE REPORTS**  
**ULTRASOUND ABDOMEN & PELVIS REPORT 3D - CT SCAN**

NAME: MRS. AMUTHAVALLI      AGE: 42 YRS / F  
 REF. BY: SELF      USG No.: 9341

**LIVER** : Normal in size, Measures 11.5 cm. Echotexture - Increased. Biliary Radicles - Normal Hepatic veins & IVC Normal. No Sol Seen.

**GB** : Distended, No Calculus, No wall thickening, No sludge / polyp seen.

**CBD** : Not dilated.

**PANCREAS** : Size & Echotexture Normal. Duct not dilated: No Lithiasis

**SPLEEN** : Normal Measuring 8.2 cm. No focal or diffuse abnormal echoes.

**R.T. Kidney** : Size Normal: Dimension 11.1 x 4.5 cm. Cortico - Medullary Echo pattern Normal. Collecting system not dilated. No calculus.

**Lt. Kidney** : Size Normal: Dimension 10.7 x 4.8 cm. Cortico - Medullary Echo pattern Normal. Collecting system not dilated. No calculus.

**Retro peritoneum** : Aorta & IVC are normal: No para Aortic Lymphadenopathy.

**Ascites** : No free fluid in peritoneal Cavity.

**RIF** : Normal, no probe tenderness is present.

**Pleural Effusion** : No Rt. / Lt Pleural Effusion.

**Bladder** : Distended. Normal UV- junction. Post void shows no residual urine.

**Uterus** : Appears normal in size Dimension 4.5 x 3.5 x 3.5 cm. Anteverted. Normal endometrium measures 5 mm

**Ovaries** : Right ovary: 2.5 x 2.0 cm. Left ovary shows a hypo echoic lesion of size 5.3 x 5.1 cm without any internal echoes.

**IMPRESSION:**

- LEFT OVARIAN LARGE CYST.
- FATTY LIVER.

DR. VENKATESH RADILOGIST.  
 26<sup>th</sup> February 2014  
**CHENNAI SCANS AND LABS**  
 No. 9, 15th Street, TANSI Nagar, 100 Feet Tharamani Road, Velachery, Chennai - 600 042. Ph. : 2243 2879.

## AFTER

treatment at Homeocare International

**AFTER REPORTS**  
**ULTRASOUND ABDOMEN & PELVIS REPORT 3D - CT SCAN**

NAME: MRS. AMUTHAVALLI      AGE: 42 YRS / F  
 USG No.: 9891

**LIVER** : Normal in size, Measures 13.1 cm. Echotexture - Increased. Biliary Radicles - Normal Hepatic veins & IVC Normal. No Sol Seen.

**GB** : Distended, No Calculus, No wall thickening, No sludge / polyp seen.

**CBD** : Not dilated.

**PANCREAS** : Size & Echotexture Normal. Duct not dilated: No Lithiasis

**SPLEEN** : Normal Measuring 9.3 cm. No focal or diffuse abnormal echoes.

**R.T. Kidney** : Size Normal: Dimension 10.8 x 4.8 cm. Cortico - Medullary Echo pattern Normal. Collecting system not dilated. No calculus.

**Lt. Kidney** : Size Normal: Dimension 10.6 x 5.2 cm. Cortico - Medullary Echo pattern Normal. Collecting system not dilated. No calculus.

**Retro peritoneum** : Aorta & IVC are normal: No para Aortic Lymphadenopathy.

**Ascites** : No free fluid in peritoneal Cavity.

**RIF** : Normal, no probe tenderness is present.

**Pleural Effusion** : No Rt. / Lt Pleural Effusion.

**Bladder** : Distended. Normal UV- junction. Post void shows no residual urine.

**Uterus** : Appears normal in size Dimension 4.6 x 3.7 x 3.7 cm. Anteverted. Normal endometrium measures 7 mm

**Ovaries** : Right ovary: 2.6 x 2.3 cm. Left ovary: 2.7 x 2.0 cm. Both ovaries and adnexa appear normal.

**IMPRESSION:**

- FATTY INFILTRATION OF LIVER.

DR. VENKATESH RADILOGIST.  
 7<sup>th</sup> July 2014  
**CHENNAI SCANS AND LABS**  
 No. 9, 15th Street, TANSI Nagar, 100 Feet Tharamani Road, Velachery, Chennai - 600 042. Ph. : 2243 2879.

# Uterine Fibroid

AFTER treatment at Homeocare International



**RAGASUMA SCAN & DIAGNOSTIC CENTRE**  
 Dr. B. VIJAYASREE      Regd. No. 34775  
 M.B.B.S., DMRD      C/o. Suguna Children's Hospital  
 Cell : 9705698486      # 6-8-90, Behind Ganesh Temple  
 M.G. Road, KOTHAGUDEM - 507 101

Patient name:      Date :5-3-2011

Age/Sex:      37 Y/ F

Ref by:      Dr. Vandanam Venkateswarlu MD.

**USG PELVIS**

**UTERUS:** Normal in size and in echotexture. Anteverted. Endometrial echo is in midline and normal. No e/o focal lesion.

**OVARIES:** Both ovaries normal in size, shape and echogenicity. No adnexal masses.

**OTHERS:** No e/o free fluid in P.O.D.

**Impressions** Normal study.

Please correlate clinically.

Dr. B. VijayaSree  
 Radiologist

## Patient Testimonial

**HOMEOCARE**

Homeocare International  
 leaders in world-class homeopathy  
 www.homeocare.in

ఈ ధౌరవనములైన కైరెక్టర్ వోమియోకర్ ఇంటర్నెషనల్  
 నాపేరు ఊమల 61-8-31. నేను ఇక్కడ ఫైబ్రాయిడ్, పై (నామీ) యూటిఆస్ (లేట్ మెంట్ కు వచ్చాను. ఇక్కడ ఎమిజి నెలలు (లేట్ మెంట్) తోనుకున్నాను. ఇప్పుడు నాపై (నామీ) యూటిఆస్ రివార్ట్ వచ్చింది. నాకు (లేట్ మెంట్) ఇచ్చిన కార్టర్. మళ్ళా నాకి వోమియోకర్ ఇంటర్నెషనల్ కి ఫోన్ చేశాను.


ఊమల.  
 16/3/2011.

# Conceive easy with Homeopathic treatment

A Case Study

A young lady presented us with Infertility. USG of abdomen was suggestive of Endometrial Hyperplasia with Cystic Ovaries. After 8 months of treatment at Homeocare International the reports showed normal endometrium and ultimately she was ready to give birth to a healthy baby. This is an example of how Homeopathy can be an effective treatment.

**BEFORE** treatment at Homeocare International



**SS Labs**  
Diagnostic and Multi Speciality Consultation

**REPORT**

Name : ██████████	Date : 3 September 2013
Age : 26yrs	
Sex : Female	Ref Dr.: HEMALATHA

**ULTRASOUND ABDOMEN & PELVIS**

**Liver** : Normal in size, echocity is normal. No focal lesions. Biliary and venous systems are normal.

**Gall Bladder** : Well distended. No calculus, no sludge.

**Pancreas** : Normal in size, head measures 14mm, body 09mm and tail 11mm. The contour and echo texture is normal. No focal lesion seen. Pancreatic duct is not dilated.

**Paraortic area** : No mass lesions/lymphadenopathy.

**Spleen** : Normal in size, measures 26mm. Its contour and echotexture is normal. No focal lesions seen.

**Kidneys** RK : Normal in size, contour & echotexture. Measures - 100mm in length, Parenchymal thickness measures 14mm. The cortico medullary differentiation is maintained.

LK : Normal in size, contour & echotexture. Measures - 81mm in length. Parenchymal thickness measures 11mm. The cortico medullary differentiation is maintained.

**Urinary Bladder** : Well distended, Normal wall thickness..

**Uterus** : Measures 73mm. in length, 44mm. A.P. and 51mm across. Endometrial thickness is 19mm..

**Ovaries** : Both ovaries are normal in size with cystic appearance.. They measure Right ovary measures 32x21mm Left ovary measures 23x21mm

**IMPRESSION: ENDOMETRIAL HYPERPLASIA WITH CYSTIC OVARIES. UPPER ABDOMINAL STRUCTURES APPEAR NORMAL.**

Dr. Moscow Mani .DNB  
sonologist


**FACILITIES :**

- LABORATORY • X-RAY • ECG • ECHO
- ULTRASOUND • TMT • CONSULTATION
- DENTAL • PHARMACY
- HEALTH CHECKS • SPIROMETRY
- HOME SAMPLE COLLECTION

No. 54/2, Shivaganga Complex, Kaggadasapura Main Road, New Thippasandara Post, Bengaluru-75.  
Ph : 080-41744529 / 25240022 Mob : 9845620353 / 57  
Email : sslabsbengaluru@gmail.com Website : www.sslabs.in

# SLE

Patient Testimonial



జి ఉమ ID NO: MPAH42

కౌన్సిల్ నాన్స్ (SLE)

వయస్సు 30

చిరునామం : ఏటాపాడు,  
Road NO: 1 J.P కాలనీ,  
H.NO: 8-183/1  
వైదరాబాదు

Source: TYP Show చిరునామం Dr Srinivas గారికి  
ఫోన్ చేసి appointment అనుకుని యింజనీరింగ్  
క్రాంతి వచ్చి క్రాంతి మెంట్ అనుకున్నాను.  
13 నెలలుగా అనుకుంటే పూర్తిగా తగ్గిపోయి,  
reports ముందుగా వచ్చాయి. ఇప్పుడు మేము  
చాలా సంతోషంగా ఉన్నాము ఈ Homeocare  
వల్ల నేను చాలా సుఖి అయిపోయి ఉన్నాను  
సొంతి నల్లంది. ఇకంటా Dr Ramdas గారి  
వద్ద క్రాంతి మెంట్ వల్ల నాన్స్ వదిలింది.

జి.ఉమా

Registered Office : # 63, Sindhi Colony, S.P. Road, Secunderabad - 500 003,  
Andhra Pradesh, INDIA. Ph : 8885037219 / 9885747979 / 9849056637  
[www.homeocare.in](http://www.homeocare.in)

**ANDHRA PRADESH**  
HYDERABAD  
VIJAYAWADA  
TIRUPATHI  
VISAKHAPATNAM  
RAJAHMUNDRY  
GUNTUR  
HANUMAKONDA

**KARNATAKA**  
BENGALURU  
HUBLI  
MANGALORE  
DAVANGERE  
**TAMILNADU**  
CHENNAI  
COIMBATORE  
MADHURAI



# SLE treated with Homeopathy

Case Study of Mrs. Uma

Here is a bit of her story. A lady aged 30 years diagnosed with SLE with significant raised ANA levels. She took treatment in Homeocare International for about 13 months and showed improvement. Her reports after treatment were completely normal.

## BEFORE

treatment at Homeocare International

Ph: 040 - 23031720 / 23030793  
Fax: 040-23030241

**Tesla Diagnostics**  
Chandanagar  
*Helps to lead a Quality Life*

Patient Name : Mrs.G UMA Bill/Req.No : 77303  
Age : 26 Years Reg.Date : 20/04/2013 12:12 PM  
Sex : Female Sample Coll.Date : 20/04/2013 12:20 PM  
Ref.By : SARITHA(HOMEOCARE INTERNATIONAL) Report Date : 23/04/2013 12:42 PM

**IMMUNOLOGY/SEROLOGY**

DESCRIPTION	RESULT	UNITS	REFERENCE RANGE
Anti ds-DNA Antibody	196.58	IU/ml	Negative : < 25 Borderline : 25 - 34.9 Weakly Positive : 35 - 99.9 Moderately Positive : 100 - 200 Strong Positive : > 200

Method: Solid Phase Enzyme Immunoassay

checked by **\*\*\* END OF REPORT \*\*\*** Authorised Signatory

\* Suggested Clinical Correlation If Necessary Kindly Discuss  
\*\*NOTE:- SAMPLE OUT SORCED\*\*

## AFTER

treatment at Homeocare International

Ph: 040-23031720, 23030793  
Fax: 040-23030241

**Tesla Diagnostics**  
Chandanagar  
*Helps to lead a Quality Life*

Patient Name : Mrs.G UMA Bill/Req.No : 148404  
Age : 30 Years Reg.Date : 21/04/2014 07:40 PM  
Sex : Female Sample Coll.Date : 21/04/2014 07:44 PM  
Ref.By : DEEPIKA Report Date : 22/04/2014 04:48 PM

**SEROLOGY REPORT**

TEST	RESULT	UNITS
Anti Nuclear Antibody	15.2	EU/ml

BIOLOGICAL REFERENCE INTERVALS  
< 20 : Negative  
20 - 25 : Equivocal  
> 25 : Positive

Method : E.L.I.S.A

---END OF THE REPORT---

DR.G.Sri Hari Rao consultantPathologist  
DR.Vasantha Indira Consultant Microbiologist  
P.Suneetha Biochemist

\* Indicates parameters are NABL Accredited Suggested Clinical Correlation If Necessary Kindly discuss

# Infertility

**HOMEOCARE**  
**arogy**  
*Be Healthy, Be Happy*

## AFTER

treatment at Homeocare International

**SS Labs**  
Diagnostic and Multi Speciality Consultation

REPORT

Name : Mrs. Uma Date : 2 April 2014  
Age : 27yrs  
Sex : Female Ref Dr.: Kavya

**ULTRASOUND ABDOMEN & PELVIS**

Liver : Normal in size, echocity is normal. No focal lesions. Biliary and venous systems are normal.

Gall Bladder : Well distended. No calculus, no sludge.  
Pancreas : Normal in size, head measures 14mm, body 09mm and tail 11mm. The contour and echo texture is normal. No focal lesion seen. Pancreatic duct is not dilated.

Paraortic area : No mass lesions/lymphadenopathy.

Spleen : Normal in size, measures 30mm. Its contour and echotexture is normal. No focal lesions seen.

Kidneys RK : Normal in size, contour & echotexture. Measures - 90mm in length, Parenchymal thickness measures 16mm. The cortico medullary differentiation is maintained.  
LK : Normal in size, contour & echotexture. Measures - 90mm in length. Parenchymal thickness measures 15mm. The cortico medullary differentiation is maintained.

Urinary Bladder : Partially filled, appears normal.

Uterus : Anteverted Measures 79mm, in length, 40mm, A.P. and 46mm across. Endometrial thickness is 7mm.

Ovaries : Both ovaries are normal in size. They measure Right ovary measures 25x22mm Left ovary measures 19x15mm

**IMPRESSION: NORMAL STUDY OF ABDOMEN AND PELVIC STRUCTURES.**

Dr. Moscow Mani, DNB  
sonologist

**SS Labs**  
Diagnostic and Multi Speciality Consultation

REPORT

NAME : Mrs. Uma DATE :  
AGE : 27years  
SEX : Female REF. Dr : HEMALATHA

**EARLY PREGNANCY SCAN FOR NUCHAL TRANSLUCENCY & NASAL BONE**  
[ L.M.P. - 22-03-14 E.D.D. 03-01-15 ]  
[ Present Gestation Age - 13 weeks 4 days ]

Single live intrauterine fetus in changing presentation.  
Foetal cardiac activity and movements are normal.  
Foetal heart rate 162 beats/min, regular.

BPD	26mm
HC	99mm
FL	10mm
AC	76mm
HC/AC	1.30
GA by USG	13 weeks 4 days

CRL-72mm  
Nuchal translucency measures 1.8mm. Nasal bone ossification is visualised.  
Estimated fetal weight : 148 gm  
Placenta is fundus-anterior. Grade 0.  
Amount of liquor is adequate.  
Cervix is normal, Internal os is closed.

**IMPRESSION :- SINGLE INTRAUTERINE LIVE FETUS CORRESPONDING TO 13 WEEKS 4 DAYS WITH NORMAL NT PARAMETER.**  
(EDD- 03- 01-2015)

Dr. Moscow Mani, DNB  
Sonologist

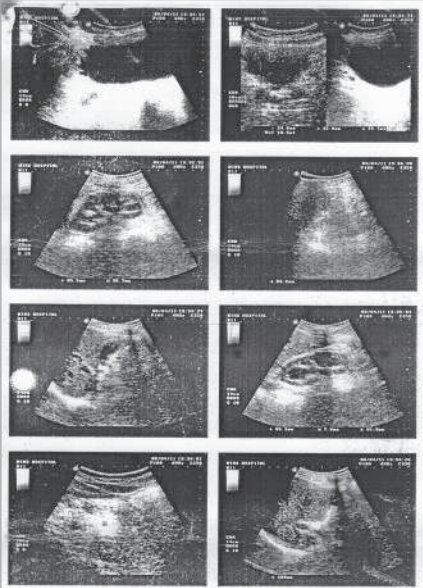
I Dr. MOSCOW MANI while conducting ultrasonography declare that I have never detected or disclosed the sex of the fetus to any body in any manner.

# Chronic Kidney Disease

## A Case Study

This case illustrates how Homeopathy works even on chronic diseases. A man presented us with chronic Kidney Disease with raised serum creatinine levels i.e., 6.4mg/dl and CT abdomen showed thickening of urinary bladder with bilateral hydronephrosis and was supposed to go for dialysis due to the risk of end-stage renal disease. After that he came with a hope to Homeocare International and started treatment, gradually he improved and serum creatinine levels came down to normal i.e., 1.3mg/dl.

### BEFORE treatment at Homeocare International



MEDICAL SCIENCES  
HYDERABAD  
RADIOLOGY & IMAGEOLOGY  
ULTRASONOGRAPHY REPORT

DATE: 8/04/2011  
US NO: 2410

ND ABDOMEN

Structure. No evidence of focal lesions / IHBD

/ wall thickening. CBD is normal.

normal in course and caliber.

caliber.

No evidence of pancreatic duct dilatation

No evidence of para aortic lymphadenopathy.

Structure. No evidence of focal lesions.

Left kidney measures: 9.5 x 3.8 cm

Increased echotexture with poorly maintained

Dilated ureters are seen.

Urinary bladder wall thickening [6 mm], floating

No evidence of calculi.

PVR - 160 cc, significant


Prostate - 20 cc, normal in size, calcifications noted within - corpora amylacea.

No evidence of free fluid noted in the abdomen.

IMPRESSION: 1] Irregular thickening of bladder wall, trabeculations and floating internal echoes - Cystitis -? Neurogenic bladder.  
2] Bilateral hydronephrosis - s/o VUR.  
3] Bilateral grade II renal parenchymal changes.  
4] Significant post void residual urine.

ADV - MCUG for further evaluation.

Dr. S. SREEDHAR



**Vijaya Diagnostic Centre**  
3-6-16 & 17, Street # 19, Himayathnagar,  
Hyderabad-29. Ph: 23420422 / 423 / 424 / 425.  
email: info@vijayadiagnostic.com  
www.vijayadiagnostic.com

Regn Date : 12/07/2013 09:38  
Name : MR. CHANDRA SHEKAR  
Regn No : 131316195  
Ref Dr : SRINIVAS V S N D

Print Date : 12/07/2013 12:31  
Age / Sex : 68 Years / Male  
Regn Centre : Secunderabad II

ULTRASONOGRAM OF THE ABDOMEN & PELVIS

History : General check up

**LIVER** Normal in size (14 cm ) and diffuse increase in echotexture. There is no suggestion of either intra or extra hepatic biliary duct dilatation. CBD and portal vein are normal. Two small well defined hypochoic lesions measuring 12 x 12 mm and 14 x 11 mm are noted abutting the medial margin of gall bladder

**GALL BLADDER** Physiologically distended and shows no evidence of calculi/inflammatory changes/mass lesion.

**PANCREAS** Normal in size, shape and echopattern.

**SPLEEN** Normal in its size and echotexture.

**KIDNEYS** **Right kidney** : 85 x 30 mm. Cortical thickness - 13 mm.  
**Left kidney** : 95 x 37 mm. Cortical thickness - 12 mm.  
Mild irregular contour of both kidneys.  
Cortical parenchymal echotexture is mildly increased.  
Preserved, Cortical parenchymal thickness of both kidneys  
Collecting system is normal. No evidence of calculi.  
No hydronephrosis in both kidneys.

**URINARY BLADDER** Wall thickness is diffusely increased 6 mm when fully distended  
Prevoid 540 cc ; Postvoid : 420 cc

**PROSTATE** Size : 32 x 32 x 33 mm. Vol ; 19 cc  
Normal in size, shape and echotexture.

No paraaortic adenopathy. No ascites.

### AFTER

treatment at Homeocare International

# Rheumatoid Arthritis

## Patient Testimonial

113

21/3/14

TESTIMONIALS :

Name of Patient : Nageshwar Rao

Age & M/F : 34 year's male,

I.D Number : HBBU 55

Date of joining and duration of trt. : 18/5/13. 9 months

Improvement : \_\_\_\_\_

Feed back : I Mr. Nageshwar Rao, I had arthritis since u-6 years multiple joint pains swelling. I took treatment in HCI Hubli. under care of Dr. Dhanashri for 6 months my blood report came to normalacy all joint pains & swelling decreased I am feeling totally better thanks for wonderful treatment, I am able to do day today activities.

Thanking you.

# A case of Rheumatoid Arthritis

A patient with Rheumatoid Arthritis suffering since 6 years came to Homeocare International, after taking treatment for about 6 months he was cured symptomatically and his reports after treatment were absolutely normal with strong hope that Homeopathy confidently works.

## BEFORE

treatment at Homeocare International

CHINIWAL DIAGNOSTIC LABORATORY  
KBCIOT HOSPITAL, ISLAMPUR CIRCLE, NEAR CHURCH, RG ROAD  
GANGAVATHI-583 227  
S. NASEEM PEERAN M.L.T. 8197393006

PT. NAME: SRI. NAGESHWAR AGE: 35Y/M DATE: 01.03.2014  
REF. BY: DR. C. B. CHINIWAL LAB. NO: 0109/14  
MBBS, D'ORTHO, DIPNBI(ORTHO)(GOLD MEDALIST)

PARAMETERS	OBSERVED VALUES	REF. RANGE
<b>HAEMATOLOGY</b>		
ESR	:38	[<15mm(M)/HR's]
<b>SEROLOGY</b>		
R A FACTOR	: "REACTIVE"	
<b>BIO CHEMISTRY</b>		
SR, URIC ACID	:9.6	[3.8-8.0MG/DL]

SIGNATURE [Lab Technician]

*Abbass Nageshwarrao*  
*BEFORE*

## AFTER

treatment at Homeocare International

AMRUTA SCAN CENTER  
DR. S. J. NAGALOTIMATH MEMORIAL LABORATORY  
Sushruta Multi Speciality Hospital Complex, P. B. Road, Vidyanagar, Hubli-580025.  
Telefax: 0836-2277501 / 02 / 03 E-mail: amrutascan@gmail.com

A.S.C No : 20421 Patient Name : Nageshwarrao G Reg. Date : 13/03/2014.  
Ref. by : Dr. Dhanashree T. M.D(HOM) 35 Years, Male.

**COMPLETE BLOOD COUNT**

Test	Result	Normal Range	Unit
Haemoglobin	: 12.6	14.0 - 17.0	gm/dl
W.B.C Count	: 9,600	4000 - 11000	cells/cmm
<b>DIFFERENTIAL COUNTS</b>			
Neutrophils	: 74	40 - 75	%
Lymphocytes	: 22	20 - 45	%
Monocytes	: 02	2 - 10	%
Eosinophils	: 02	01 - 06	%
Basophils	: 00	0 - 1	%
E.S.R	: 14	0 - 15	mm/1st hr
Serum Calcium	: 9.8	8.2 - 10.4	mg/dl
R.A. Factor (quantitative)	: NEGATIVE		

Dr. Poornima Jawali, M.D.(Path) Consultant Pathologist. Microbiologist

*After*

# Chronic Kidney Disease

HOMEOCARE  
arogya  
Be Healthy, Be Happy

Patient Testimonial

I.D.N.Lp20.

Best impression - date. 15-09-2013.

I, C. Chandrashekhar, R/o Chogunta, Dist. Medak.

I, I.D.N.20, here by declare my experience, and treatment taken by the doctors, Homeocare international, at Begumpet. I was suffering with kidney problems since last 3 years. I have taken medicines and treatment at NIMS hospital Hyderabad but not totally cured. After my admission at Homeocare international, Begumpet, I have been totally cured, I am very very happy with the staff and doctors hospitality of Dr. P. Anil Kumar at this centre now I have no any health problem. with in 5 months all my reports are normal. I shall not forget your service in my life and I shall be always grateful to you. As far as possible I will also tell my experience to needy patients.

May God Bless you. Wish you all the best

Thank you.

Yours faithfully,  
C. Chandrashekhar

HOMEOCARE INTERNATIONAL  
LEADERS IN WORLD-CLASS HOMEOPATHY  
An ISO 9001-2008 Certified Clinic with German Accreditation

Registered Office : # 63, Sindhi Colony, S.P. Road, Secunderabad - 500 003, Andhra Pradesh, INDIA. Ph : 8885037219 / 9885747979 / 9849056637  
www.homeocare.in

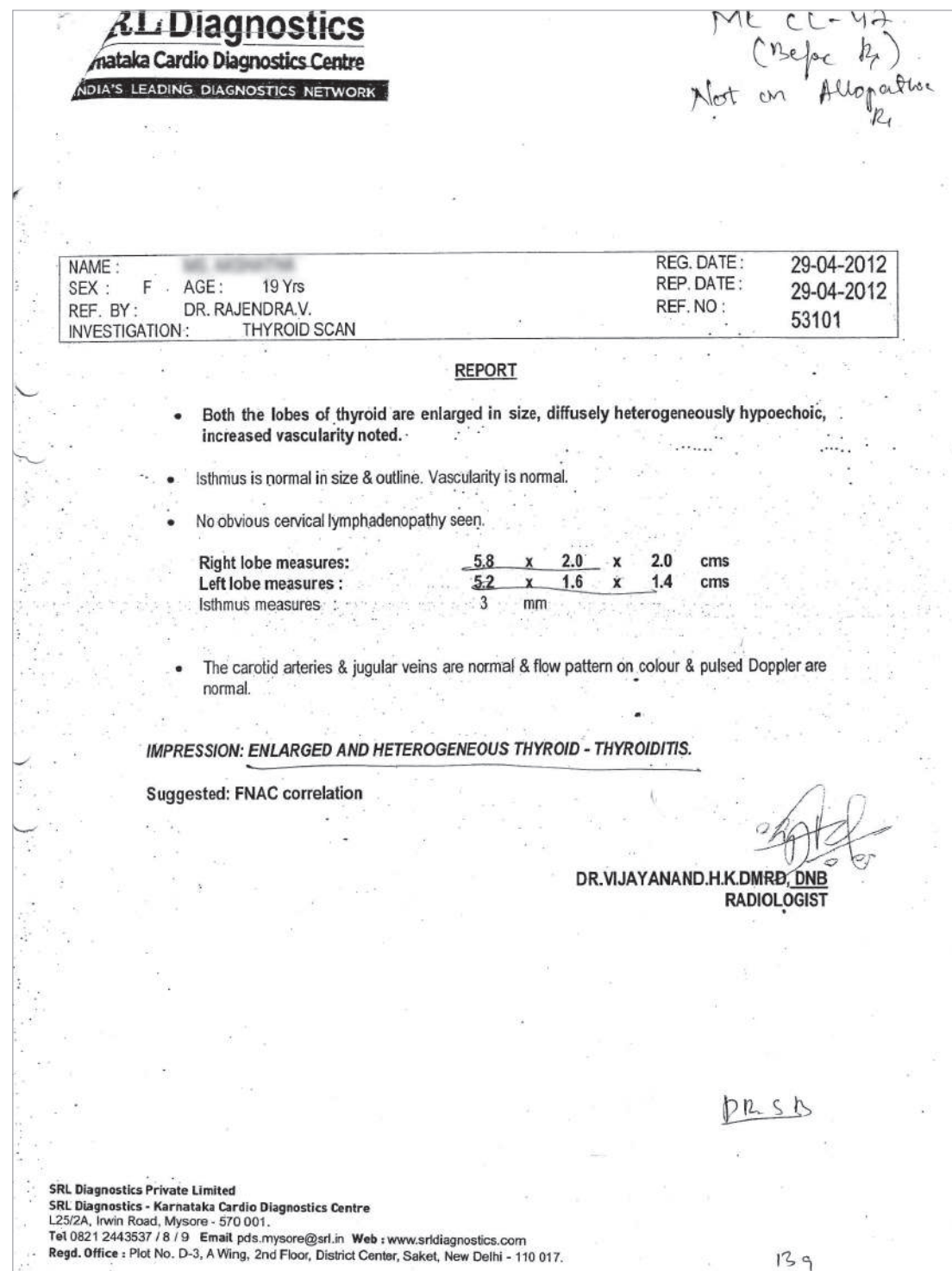
ANDHRA PRADESH	BENGALURU
HYDERABAD	HUBLI
VIJAYAWADA	MANGALORE
TIRUPATHI	DAVANGERE
VISAKHAPATNAM	TAMILNADU
RAJAHMUNDRY	CHENNAI
GUNTUR	COIMBATORE
HANUMAKONDA	MADHURAI

# Thyroiditis cured with Homeopathy

A Case Study

**BEFORE** treatment at Homeocare International

A 19-year old girl presented us with Thyroid enlargement. Ultra sound studies suggested diffuse Thyroiditis. After a course of 1-year treatment at Homeocare International, she was sent again for USG of Thyroid which confirmed both lobes of thyroid as normal in size and echo texture.



## How Homeopathy works on Arthritis?

Homeopathy has a lot of scope in every case of Arthritis.

It is the only science that deals with the immune system.

Homeopathic medicine is energy boosting, unlike any chemical which directly stimulates our disturbed immune power. It is able to fight any changes that occur in our body.

Homeopathy treats the person in disease, not the disease in which it boosts up natural immune power of body and self cure takes place without creating any side effects, what is called as constitutional approach.

### With the help of Constitutional Medicine we can:

1. Control the progress of disease
2. Prevent frequent relapse of symptoms
3. Can prevent long-term need of immunosuppressive drugs, pain-killers, antibiotics and steroids
4. Reduce heredity effects which is known to cause the disease
5. Helps in combating patient-stress and free up from emotional stress, which is one of the most important risk factors for any disease

### Rheumatoid Arthritis:

Rheumatoid Arthritis is not due to aging process but can occur at any age. It is an autoimmune disorder in which our body's immune system mistakenly attacks its own tissues. The lining of a joint becomes inflamed that causes stiffness and pain in the joints. People with Rheumatoid Arthritis may fall generally ill and experience few symptoms such as fatigue, fever and lack of appetite. In advanced or untreated cases it leaves permanent stiffness and deformity in joints.

### Psoriatic Arthritis:

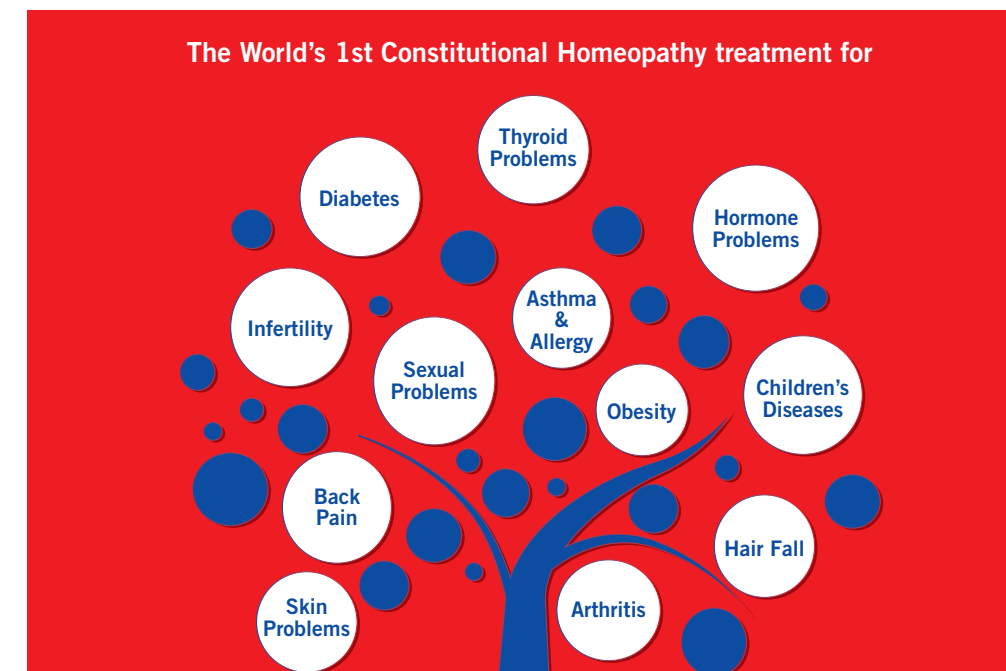It is a type of Arthritis characterised by pain and swelling of joints in association with scaly plaques of the skin. In many cases skin symptoms precede the development of Arthritis by several years.

### Gout:

Gout can affect any joint. It usually starts in the big toe but may move to your ankles, knees, elbows, hands and other joints. Gout is caused due to excess uric acid in blood which gets deposited in the joints causing damage to it. Symptoms often are red, swollen, throbbing and incredibly painful joint. Gout can cause permanent damage to the affected joint if not treated properly.

### How is Arthritis diagnosed?

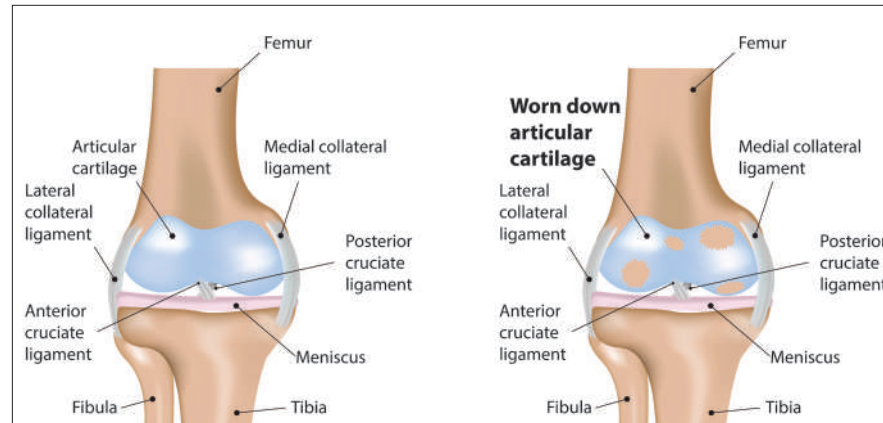
Arthritis can be diagnosed by history and symptoms given by the patient. Clinical examination by the doctor during which he will check for limited range of motion in the joint, swelling, warmth or redness around the joints. Apart from this your doctor will advise routine blood investigations and fluid analysis and imaging scans such as X-Ray, MRI, CT scan etc.



# Arthritis, Let The Healing Begin

The very essence of life is to stay healthy, move freely and remain away from health issues that affect the feeling of well being. But diseases of joints remove this sense of well being and impair the quality of life.

Nearly one-third of elders experience this due to the common cause of unhealthy lifestyle and nutrition. Here's some striking introduction to Arthritis and tips to get rid of the disease.



## What is a Joint?

It is the place where two bones meet. Joint is a complex structure made up of bone, muscles, ligaments, cartilage and tendons which are designed to allow bones to move in a definite direction. The ends of your bones are covered with a thin layer of cartilage. This cushions the joints and helps to spread the load evenly when you put pressure on it. It's smooth, slippery surface allows your bones to move freely without friction. Surrounding the joint is a tough, fibrous layer called the capsule, which stops your bones from moving too much. The inner surface of the joint capsule produces a thick fluid that nourishes the cartilage and lubricates the joints.

## What is Arthritis?

Arthritis is a joint disease where these structures and functions of the joint are affected and gives rise to the pain, swelling, stiffness and finally stops the joint working properly.

## What are the causes of Arthritis?

The following factors may contribute towards a higher risk:

1. Your genetic makeup
2. A physically demanding job, especially one with repetitive movements
3. A previous injury
4. Some infections or allergic reactions may cause Arthritis
5. Certain foods can either bring on Arthritis symptoms, or make existing one worse
6. Obesity which places extra strain on joints
7. Arthritis may also be caused by auto immune diseases
8. Combination of above factors working together

## What are the signs and symptoms of Arthritis?

1. Joint pain
2. Swelling of the affected joints
3. Stiffness of joint
4. Warmth around the joint
5. Restricted movements
6. Deformities in advanced stages

## What are the types of Arthritis?

Arthritis belongs to the group of musculoskeletal disorders consisting of not less than 100 varieties. Of these most common joint disorders includes Osteoarthritis, Rheumatoid Arthritis, Psoriatic Arthritis, Gout.

## Osteoarthritis:

Osteoarthritis occurs when the cushion of the joint-cartilage get damaged. The raw area that results, causes the bone to rub painfully on the other bone. Osteoarthritis is a degenerative disease, it becomes steadily worse over time and age. People who are overweight put extra pressure on their hip, knees and other weight bearing joints, this can contribute to the damage of the fibrous joint cartilage. Other causes of osteoarthritis include sports related injury and physical trauma by accidents. Occupation that depends on heavy physical labour are another common culprit. Osteoarthritis is more common in older women due to shortage of oestrogen.

# Thyroiditis

**AFTER** treatment at Homeocare International

MCCL-47 (Office 5) ⑤

**KANVA DIAGNOSTIC SERVICES PVT LTD.**  
NO. 2/10, Dr. Rajkumar Road, 4th N Block, Rajaji Nagar, Bangalore - 560010

Patient Name	[REDACTED]	Age	19 years
Patient I D	K1079920	Sex	F
Ref.By Doc	DR SNEHA	Date	11/Apr/2013

**THYROID ULTRASONOGRAPHY.**

Both lobes and isthmus of thyroid are normal in size and show homogenous echotexture. **There is no focal lesion.**

**MEASUREMENTS :**

	LENGTH	AP	TRANS
Right lobe	4.0	1.7	1.7 cm
Left lobe	3.9	1.7	1.8 cm

Carotid artery and jugular vein are normal.

There is no evidence of significant cervical lymphadenopathy.

**IMPRESSION :**

**NO ABNORMALITY DETECTED.**

DR SUDHAKAR, DMRD,  
RADIOLOGIST

br-sh

# A new path to cure Gouty Arthritis

A Case Study

This is a case of Gout which is relieved. Homeocare International offers solutions for all kinds of Arthritis. Homeopathic medicines not only help to relieve pain but the advanced genetic constitutional homeopathic treatment helps in preventing future progression and makes life pain-free.

## BEFORE treatment at Homeocare International

**SAPTAGIRI PATHOLOGICAL LABORATORY**  
H.No. 3-3-196, Behind Civil Hospital, Near Nehru Statue, Sawaran Street, Karimnagar - 505 001.

Patient Name : Mr. Ashok Reddy      Age :      Gender : Male  
Referred By : SELF      *Before*      Reg Date : 08-May-2014  
Patient Id : 140508-006

Department of Bio-Chemistry      *JBHAG 35*

Investigation	Result	Normal Ranges
Serum Uric Acid	9.67 mg/dl	Male: 3.4 - 7.0 mg/dl. Female: 2.5 - 5.7 mg/dl

✓ End of Report  
Lab Incharge

## AFTER treatment at Homeocare International

**యశోద డయాగ్నోస్టిక్ సెంటర్**  
**YASHODA Diagnostic Centre**  
Dr. V. Sreenivas M.D. Pathology (NIMS)  
Dr. M.V. Mohan M.D. Biochem. (Osmi.)

Name : Mr. ASHOK REDDY      Age & Sex : 22 Years /Male      Date : 27-Jun-2014  
Ref. Dr : SELF      *After*      Lab No : 14-0627010

CLINICAL BIOCHEMISTRY      *JBHAG 35*

Test Name	Value	Units	Reference Range
URIC ACID	5.9	mg/dL	Adult Male: 3.5 - 7.2

End of the Report  
SPECIMEN TYPE : Serum

# Gouty Arthritis

Patient Testimonial

**HOMEOCARE**  
**arogyā**  
Be Healthy, Be Happy

**HOMEOCARE INTERNATIONAL**  
Pt. Ltd.  
LEADERS IN WORLD-CLASS HOMEOPATHY  
An ISO : 2008 Certified clinics with German Accreditation

Dt: 30.6.2014

I P. Ashok Reddy from Karimnagar, my age is 22 years. has been very interested in sports (Boxing), I take very high Protein diet, but it resulted me in the form of gouty arthritis, to cure it I showed in many hospitals but I was temporarily cured the problem. It didn't give me any satisfaction as they used steroids to reduce gout pain in joints temporarily. By suggestion of my brother I came to know about Homeocare International. Then one day I consulted the J.hills branch Dr. Suresh Reddy by listening to his words I got hope on him, then immediately I started my treatment. At treatment starting time my uric acid level is 9.6 mg/dl, regularly I taken the doctor prescribed medicine, by the time of 30 days my uric acid level now reduced to 5.9 mg/dl, now I am feeling happy and continuing in world class homeopathy. I specially thank Dr. Suresh Reddy and staff.

Thanking you Dr. Suresh Reddy  
J.hills branch.

P. Ashok Reddy  
Karimnagar  
9908726540.

Registered Office : # 63, Sindhi Colony, S.P. Road, Secunderabad - 500 003,  
Andhra Pradesh, INDIA. Ph : 8885037219 / 9885747979 / 9849056637  
[www.homeocare.in](http://www.homeocare.in)

**ANDHRA PRADESH**  
HYDERABAD  
VIJAYAWADA  
TIRUPATHI  
VISAKHAPATNAM  
RAJAHMUNDRY  
GUNTUR  
HANUMAKONDA

**KARNATAKA**  
BENGALURU  
HUBLI  
MANGALORE  
DAVANGERE  
**TAMILNADU**  
CHENNAI  
COIMBATORE  
MADHURAI